

# STUDY ON ETIOLOGY OF INTESTINAL OBSTRUCTION

AUTHOR: Dr. A Muthuvinayagam, MS  
PERIOD OF STUDY: October 2016 to October 2017  
PLACE OF STUDY: Thanjavur Medical College Hospital

## ABSTRACT

This study attempts to evaluate the common causes of intestinal obstruction in patients presenting to Thanjavur Medical College Hospital. The results were:

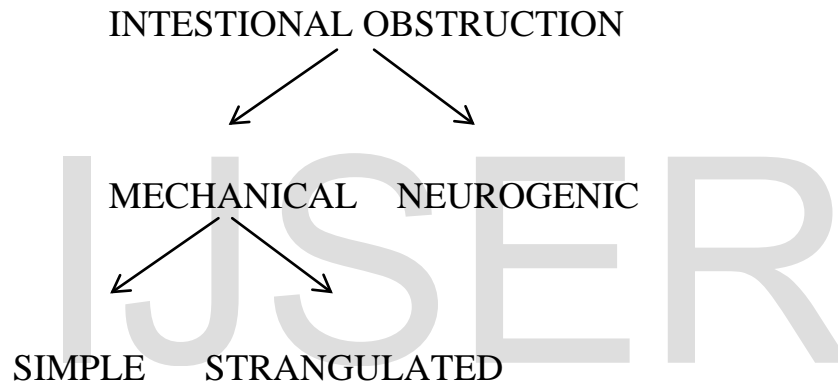
Among the causes of Acute Intestinal obstruction, 64.88% is contributed by Small bowel obstruction and 35.11% by Large bowel obstruction. The major cause of acute intestinal obstruction is still External hernia (30.53%) here. Among this, inguinal hernia alone accounts for 35.29% of small bowel obstruction. Adhesive obstruction accounts for 25.88% of small bowel obstruction, of which the Post – surgical adhesion is the major cause. Sigmoid volvulus contributes 16.79%, next only to large bowel neoplasm contributing 18.32% to intestinal obstruction. Clinical parameters fail to differentiate between simple and strangulated obstruction early. Plain X – ray abdomen is a valuable in the diagnosis of the acute obstruction (73%) and hence it is considered as necessary minimal investigation before surgery. Early surgical intervention and antibiotics has reduced the mortality of the simple bowel obstruction.

## AIM OF THE STUDY

1. To evaluate the common causes of acute intestinal obstruction in this region.
2. To identify the etiology
3. To evaluate the value of plain X ray abdomen erect in intestinal obstruction

## CLASSIFICATION AND ETIOLOGY OF INTESTINAL OBSTRUCTION

Intestinal obstruction is classified into two main types.



### MECHANICAL OBSTRUCTION:

In Mechanical obstruction, the intestinal contents are prevented from passing along the bowels by acute obstruction of the lumen of the gut.

### NEUROGENIC OBSTRUCTION:

In neurogenic obstruction, the peristalsis ceases and no true propulsive waves occur and so the intestinal contents do not traverse the bowel.

Mechanical obstruction is further classified: -

According to site of obstruction it is classified into

1. Small bowel obstruction            High
2. Large bowel obstruction            Low

**According to etiology:** This is the most useful type of classification which reveals the underlying cause for obstruction.

1. Causes in the Lumen            Gall stone, Food bolus, Faecal Impaction,  
Barium, bezoar, worms etc.
2. Causes in the wall            Congenital atresia, Bowel neoplasms,  
Inflammatory strictures etc.
3. Causes outside the wall    Strangulated Internal hernia, external hernia,  
Obstruction due to adhesions, volvulus,  
Intussusception

## MATERIALS AND METHODS

A total of 131 cases of acute intestinal obstruction admitted in all surgical wards, Thanjavur Medical College Hospital, Thanjavur, over a span of 1 year from October 2016 – October 2017. Both men and women more than 15 years of age totaling 131 cases with features of acute intestinal obstruction were chosen. The paediatric patients were not included in this study.

The Age, Sex detailed History relevant to the etiology were noted. The characteristic clinical features of acute intestinal obstruction were abdominal pain, vomiting, constipation / obstipation, Abdominal distension and clinical signs including Fever ( $>37.2^{\circ}\text{C}$ ). Tachycardia ( $>100/\text{mt}$ ), Palpable abdominal mass if any were noted.

All the patients were subjected to investigation while resuscitative measures were on progress

1. Urine – albumin, sugar
2. Hb%
3. Blood Grouping with typing
4. WBC count
5. Blood – urea, sugar, Serum Creatinine, Electrolytes – in cases with severe dehydration

6. X – ray chest PA view
7. ECG
8. Plain X – ray abdomen erect and supine position and results were recorded.

After adequate preoperative preparation, all patients were subjected to surgical procedures appropriate to the condition and preoperative pathology were noted. The etiological incidence, Sex incidence, Age incidence, incidence of strangulation, value of plain X – ray Abdomen in diagnosis of acute intestinal obstruction, importance of early treatment were studied.

## **TREATMENT**

### **Inguinal hernia**

Among the cases of inguinal hernia those present with simple obstruction all underwent simple reduction of contents and hernioplasty. For strangulated cases, resection of the non viable intestine and end to end anastomosis, followed by Herniorrhaphy was done.

### **Femoral hernia**

For femoral hernias with non viable bowel, resection and anastomosis followed by repair was done. For those cases who developed post operative adhesive intestinal obstruction, Laparotomy was done.

### **Para umbilical hernia**

For the Para umbilical hernia with simple obstruction, mesh repair was done. Vacuum drainage was kept.

### **Incisional hernia**

Cases present with simple obstruction or with strangulation underwent repair either anatomical or with mesh.

### **Post surgical adhesion**

Two cases, were treated conservatively. In those requiring laparotomy, 4 were with simple obstruction and 2 were strangulated. For simple obstruction, adhesiolysis was done. 2 strangulated cases underwent resection and anastomosis. In the post operative period, 3 had wound infection.

### **Congenital bands**

Laparotomy was done in all the cases, those present with simple adhesion and adhesiolysis was done and for 1 case, resection and anastomosis was done. 3 cases developed post operative wound infection.

### **Tuberculous abdomen**

Laparotomy was done in all and was found to be simple obstruction. So biopsy was taken from the omentum, lymph nodes and sent for histopathological examination. Subsequently they were put on anti tuberculous drugs. Viz Rifampicin, I.N.H., Ethambutol and Pyrazinamide.

### **Small bowel volvulus**

In these 2 cases, laparotomy was done, in which non viable bowel was resected and adhesions were released followed by end to end anastomosis.

### **Meckel's diverticulum**

In the 1 case with simple obstruction, Meckel's diverticulectomy was done.

### **Intussusception**

In the 2 cases, both were with gangrenous jejunum for which resection and anastomosis was done. Their post operative period was uneventful.

### **Ileosigmoid knotting**

In the 1 case, resection of knot along with ileum and sigmoid colon with end to end anastomosis was done.

### **Miscellaneous**

#### **Small bowel tumours**

Only one case was found during Laparotomy and the tumour was found to occupy jejunum which was resected and end to end anastomosis was done. Specimen was sent for histopathological examination.

#### **Jejuno – gastric intussusception**

1 case underwent partial gastrectomy and resection of the efferent loop with reconstruction of gastro jejunostomy.



## **Large bowel obstruction**

### **Sigmoid volvulus**

In the 22 cases, 19 were simple and 3 were with strangulated bowel, all patients underwent laparotomy and resection of sigmoid colon, of which 8 developed post operative wound infection and 3 died in the post operative period.

### **Malignant growth of the large bowel**

Out of the 24 cases with large bowel malignancy causing obstruction, definitive 1 stage resection was done in 5 cases. 3 patients ended in Hartmann's procedure. 12 cases underwent temporary diversion colostomy/ileostomy and 4 cases underwent ileo transverse anastomosis.

## **RESULTS**

### **SMALL BOWEL OBSTRUCTION**

In our series it contributes to 85 cases in total. In this series the following are major causes of small bowel obstruction.

- A. External hernia – 40 cases
- B. Adhesion and bands – 22 cases
- C. Tuberculous Abdomen – 15 cases
- D. Small bowel volvulus – 2 cases
- E. Meckel's Diverticulum – 1 case
- F. Intussusception – 2 cases
- G. Ileo Sigmoid Knotting – 1 case
- H. Miscellaneous

Jejuno – Gastric Intussusception – 1 case

Small bowel Tumours – 1 case

### **LARGE BOWEL OBSTRUCTION**

It contributes to 46 cases in total. In our series the following are major causes of large bowel obstruction.

- a. Sigmoid volvulus – 22cases
- b. Malignant growth of large bowel – 24 cases

## DISCUSSION

In our study of study of Acute Intestinal obstruction, small bowel and large bowel obstruction were recorded contributing 64.88% and 35.11% respectively, in contrast to Western literature, where 70% of obstruction occur in small bowel and 30% in large bowel. The difference of contribution of large bowel obstruction is due to low prevalence of large bowel neoplasms, diverticulitis and inflammatory bowel disease but higher dietary fiber intake in our part of the world as compared to Western countries.

In this study, External hernia contributes 30.53% to Acute Intestinal obstruction. Inguinal hernia contributes to 75% of external hernia causing obstruction and 35.29% of total small bowel obstruction. It ranks FIRST among the causes of Acute intestinal obstruction. This is contrast with the world literature, where adhesive obstruction is the prime cause (40%), and hernia becomes the second cause of obstruction (25%). We have encountered only 3 cases of femoral hernia and 2 cases of paraumbilical hernia and 5 cases of incisional hernia.

The high prevalence of inguinal hernia causing obstruction is attributed to

- a) Inadequate knowledge about the disease proper because of low literacy.
- b) Reluctance of patient to undergo Elective repair of hernia
- c) High prevalence of Chronic cough (viz. tuberculosis etc.)

Even though the prevalence of Inguinal hernia causing obstruction is high, the strangulation rate has come down dramatically to 13.33% due to

- a) Early arrival of patient once obstruction occurs, even though he doesn't care it before.
- b) Early recognition and immediate treatment.

In our study, Adhesive obstruction accounts for 25.88% of acute intestinal obstruction. Among this 50% were due to Post – surgical adhesion, 16.6% due to post inflammatory adhesion and 33.3% due to congenital band. Increased incidence of Caesarean sections, Hysterectomies and P.I.D. accounts for more incidence of adhesive obstruction in females.

Still the Abdominal tuberculosis account for 17.6% in total as a cause of small bowel obstruction. In our study, adhesiolysis could be contemplated in 3 cases because of extensive adhesions.

The occurrence of small bowel volvulus was 2.35% in contrast to Agarwal and Misra's observation who reported 20%.

Surprisingly we have come across 2 cases of Intussusception (2.35%) and 1 case of Meckel's diverticulum (1.17%) causing obstruction. One case of small bowel tumour (1.17%) was encountered.

Large bowel Obstruction, accounted for 35.11% of acute intestinal obstruction.

In this series, Sigmoid volvulus contributes for large bowel obstruction accounting for 44% and Neoplasm of large bowel contributes to 48%. The high incidence of Sigmoid volvulus in our place are due to

- 1) Diet containing large amount of vegetables, roughages that overloads the colon causing chronic dragging and lengthening of the loop.
- 2) Thickened, hypertrophied sigmoid colon.
- 3) Long freely movable sigmoid loop on a long and freely movable redundant mesosigmoid.

The clinical parameters like continuous pain, fever ( $>37.2^{\circ}\text{C}$ ) tachycardia ( $>100/\text{mt}$ ), palpable abdominal mass enable us to detect the presence of strangulation in about 38% of cases, that too mainly in external hernias. Shatila and Chamberlain, Sarr et al in a large series highlighted the failure of these clinical parameters to differentiate between simple and strangulated obstruction.

Plain X – ray Abdomen is still valuable in diagnosing the bowel obstruction. In our study, we were able to get multiple fluid levels in radiological picture in about 73% of cases. We haven't got positive air – fluid level in early stage of obstruction in cases of inguinal hernia. But clinical correlation along with

radiological positively increases the accuracy of diagnosis. But exact localization of obstruction necessitates other complementary investigations.

Early recognition by the patient and prompt treatment by surgeon gives good reward and decreases the mortality.

IJSER

## CONCLUSION

1. Among the causes of Acute Intestinal obstruction, 64.88% is contributed by Small bowel obstruction and 35.11% by Large bowel obstruction.
2. The major cause of acute intestinal obstruction is still External hernia (47.05%) here. Among this, inguinal hernia alone accounts for 35.29% in total.
3. Even though the inguinal hernia causing obstruction is highly prevalent, the Strangulation rate comes down dramatically to 13.33% (12) cases.
4. Adhesive obstruction accounts for 25.88% in total, of which the Post – surgical adhesion is the major cause.
5. Sigmoid volvulus ranks fourth in etiology of acute intestinal obstruction contributing 16.79%, next only to large bowel neoplasm contributing 18.32%.
6. Sigmoid volvulus contributes to large bowel obstruction accounting for 47.82% of large bowel obstruction and Neoplasm contributes to 52.17%.
7. Clinical parameters fail to differentiate between simple and strangulated obstruction exactly.
8. Plain X – ray abdomen is a valuable in the diagnosis of the acute obstruction (73%) and hence it is considered as minimal investigation before surgery.

## BIBLIOGRAPHY

1. Alfred Cuschieri, Disorders of Abdominal wall and Peritoneal cavity, Intestinal obstruction in Sir Alfred Cuschieri's "Essential Surgical Practice" Higher Surgical Training in General Surgery" fourth edition, page 156-162.
2. Bizer L.S, Liebling RW, Delaney HM: Small bowel Obstruction. Surgery 89: 407-413, 1981.
3. Brodin RE: The role of GI tube decompression in the treatment of Mechanical intestinal obstruction. Am. Surgeon 49: 131-137, 1983.
4. Bruce G. Wolff and Anne Mary Boller, Large bowel obstruction, Acute Colonic Pseudo Obstruction, Colonic Volvulus in Current Surgical Therapy by John L. Cameron, ninth edition, page 189-197.
5. Das, P., Shukla HS: Clinical diagnosis of Abdominal Tuberculosis Brit. J. Surg. 63: 941, 1976.
6. Danekar GW, Carlson GW, Hohn DC, Lynch P, Levin B: Endoscopic Laser.
7. Recanalization is effective for prevention and treatment of obstruction in sigmoid and rectal cancer. Arch. Surg. 1991 Nov. 126 (11): 1348-52.
8. Edward E. Whang, Stanley W. Ashley and Michael J. Zinner, Small bowel obstruction in Schwartz's Principles of Surgery, eighth edition, page 1027-1032.
9. Kelly M. Bullard and David A. Rothenberger, Volvulus of Sigmoid, Caecal Volvulus, Colonic pseudo – obstruction, ostomies, resections, therapy for rectal and colonic carcinoma in Schwartz's Principles of surgery, eighth edition, page 1055-1117.
10. Kurtis A Campbell, Small Bowel Obstruction in Current Surgical Therapy by John L. Cameron, ninth edition, page 117-120.



11. Goarlav, Barmia NN, Domanski BV, Esebua BA: Surgical Treatment of acute intestinal obstruction. *KlinKhir* 1991; (4): 1-3.
12. Harlow CL, Stears RL, Archer PG: Diagnosis of bowel obstruction on plain abdominal radiographs: Significance of air–fluid levels at different heights in the same loop of bowel *AJR Am. J. Roentgenol* 1993. Aug. 161 (2): 291-5.
13. Harlod Ellis, in Maingot's Abdominal Operations, 10<sup>th</sup> edition, P. 1159-1172, 1391 – 1402.
14. Iko Bo, Teal JS, Siran SM: Computed Tomography of adult intussusception clinical and experimental studies, *AJR* 143: 769-772, 1984.
15. Lelcuk S, Klauser JM, Merhan A. Endoscopic decompression of acute colonic obstruction. *Ann. Surg.* 203: 292-294, 1986.
16. Liu MY, Lin HH, WU CS, Jan YY, Wang KL: Etiology of Intestinal Obstruction – 4 years experience. *Chang Kang* 1 H such 1990 Sep. 13 (3): 161-6.
17. Lund L, Gandrup P, Baslev I: Colonic ileus – Treatment of colonic ileus, a 10 year patient material. *UgeskrLaeger* 1993 Apr. 26:155 (17): 1281-4.
18. MandeepSaund and David I. Soyvel, Bowel obstruction in Greenfield's Surgery "scientific principles and practice" fourth edition 767-787.
19. Marc Christopher Winslet, intestinal obstruction in Bailey and Love's Short Practice of Surgery 25<sup>th</sup> edition, page 1188-1203.
20. Mark Evers B, small intestine obstruction in Sabiston's Textbook of Surgery 18<sup>th</sup> edition, page 1289-1297.
21. Munro. A.A., Intestinal obstruction in Hamilton Bailey's Emergency surgery, thirteenth edition, page 420-445.

22. Pujari B.D., Abdominal Tuberculosis in The ASI textbook of surgery, 2003, page 501-503.
23. Rebekah R. White and Danny O.Jacobs, small bowel volvulus in Shackelford's Surgery of the Alimentary Tract, sixth edition, page 1035-1041.
24. Robert J. Fitzgibbons, Jr. Charles J. Filipi and Thomas H. Quinn, Hernia accident (incarceration, bowel obstruction, strangulation), groin hernias in women, Schwartz's Principles of Surgery, eighth edition, page 1355-1358, 1390.
25. Scott G. Houghton, Antonio Ramos De La Madena Ardlm, Michael G. Sarr, Bowel obstruction in Maingot's Abdominal Operation eleventh edition; page 479-508.
26. Scott Helton W and Piero M Fisichella, intestinal obstruction in ACS – Surgery sixth edition, page 514-533.
27. Simon Paterson – Brown, Benjamin N.J. Thomson, in intestinal obstruction, in The New Airs Companion in surgical studies, third edition, page 585-590.
28. Soo Y. Kin and Jon B. Morris, small bowel obstruction, in Shackelford's Surgery of the Alimentary Tract, sixth edition, page 1025-1034.
29. Tehemton E. Udawadia and Rushad T. Udawadia, small bowel obstruction, The ASI textbook of Surgery, 2003 page 443-448.
30. Thomas A. Miller and Jeannie F. Savas, Post Gastrectomy syndromes in Shackelford's surgery of the Alimentary Tract, sixth edition, page 879, 880.